

## EXPERIENCE OF USING OPTICAL COHERENCE TOMOGRAPHY IN CORNEAL INJURIES

**Gavrylyak I. V.** <https://orcid.org/0009-0005-6617-6038>

**Zhaboiedov D. G.** <https://orcid.org/0000-0002-4212-8403>

**Greben N. K.** <https://orcid.org/0009-0001-9049-6374>

*Bogomolets National Medical University, Kyiv, Ukraine*

*irengavriyak19@gmail.com*

**Background.** Eye trauma is one of the most common causes of monocular visual impairment and blindness worldwide. Modern classification divides eye trauma into two groups: open (penetrating) and closed (non-penetrating) eye trauma. During the diagnostic phase, it is important to thoroughly examine and establish the correct diagnosis according to the existing classification, which affects the further patient management and treatment outcomes. Optical coherence tomography (OCT) allows for real-time imaging of eye tissues with high resolution. In our study, we present our experience in using optical coherence tomography in cases of traumatic corneal injuries as an additional method for assessing the depth and extent of damage and monitoring corneal erosion healing.

**Aim.** To utilize optical coherence tomography of the anterior segment of the eye for the diagnosis and assessment of corneal wound healing processes.

**Materials and Methods.** The research involved 46 patients with non-penetrating corneal injuries who were observed at the clinics of Bogomolets National Medical University. A control group consisting of 15 healthy patients was also included in the study. Data collection included patient demographic information, occupation, mechanism and duration of the trauma, the presence of recurrences, and the period of seeking medical assistance. All patients underwent visual acuity assessment, biomicroscopy, evaluation of the conjunctiva and corneal condition, and fluorescein testing. Using Optical Coherence Tomography (OCT) of the anterior segment, we monitored corneal thickness and the size of the epithelial defect before and after treatment.

**Results.** In optical coherence tomography of traumatic corneal erosion, in most cases, a defect in the epithelium of irregular shape with uneven edges, an irregular mixed anterior surface of the stroma, non-uniform reflectivity of the stroma, and corneal thinning were visualized. After treatment, the results corresponded to corneal epithelialization: thick intact epithelium, hyperreflective stroma, and a demarcation line confirming the wound healing process. After treatment, the corneal thickness was restored to  $(529 \pm 144 \mu\text{m})$ , which is comparable to the thickness of a healthy cornea.

**Conclusion.** Optical Coherence Tomography (OCT) is an informative supplementary diagnostic method for corneal injuries, allowing for the assessment of corneal morphology, including the condition of the basal membrane, corneal thickness, and epithelialization. Based on these findings, we can predict the course of corneal trauma and its potential consequences, enabling us to adjust treatment strategies to prevent the development of fibrosis and minimize the long-term effects of the injury.

**Keywords:** eye trauma, corneal erosion, optical coherence tomography, corneal epithelialization.

**Background.** Eye trauma is one of the most common causes of monocular visual impairment and blindness worldwide. Each year, 55 million people suffer eye injuries that result in temporary or permanent disability [1,2]. Modern classification divides eye trauma into two groups: open (penetrating) and closed (non-penetrating) trauma. This classification was introduced and approved in 1996 in accordance with the recommendations of the United States Registry of Trauma and the terminology of Birmingham Eye Trauma of the International Society of Eye Trauma, under the leadership of Professor Kuhn. Non-penetrating eye trauma includes contusion and erosion, while open globe eye trauma encompasses penetrating, perforating, with a foreign intraocular body, or without one [3]. During the diagnostic phase, it is crucial to conduct a thorough examination and establish the appropriate diagnosis based on the existing classification, as it significantly influences the subsequent patient management and treatment outcomes. In cases of traumatic eye injuries

where erosion is superficial and does not involve the basal membrane, the corneal wound typically epithelializes within 48-72 hours, restoring its structure and transparency. However, in cases of deep corneal damage, pathological regeneration may occur, leading to the development of fibrosis, impaired transparency, and reduced visual acuity.

Typically, routine ophthalmological diagnostic methods are used for the diagnosis of traumatic eye injuries, including visual acuity assessment, biomicroscopy, and corneal fluorescein staining [5]. Additional visualization methods employed in cases of eye trauma include X-ray imaging, computed tomography (CT), magnetic resonance imaging (MRI), ultrasonography, and optical coherence tomography (OCT). The first three methods are useful for determining the localization of foreign bodies in eye injuries, while the latter methods allow for the assessment of the structure of both the anterior and posterior segments of the eye.

Optical Coherence Tomography (OCT) allows for real-time, high-resolution imaging of eye tissues. OCT is a diagnostic method that was initially developed for visualizing the posterior segment of the eye in 1991 [6,7]. With advancements in technology, OCT has shown great potential for imaging the anterior segment of the eye, including the conjunctiva, corneal layers, sclera, and anterior chamber angle. Current applications of anterior segment OCT enable measurements of corneal thickness, the diagnosis of keratoconus, and the assessment of the anterior chamber angle in glaucoma diagnosis [7]. In our research, we present our experience in using OCT for traumatic corneal injuries as an additional method to assess the depth and extent of damage and to monitor the healing process of corneal erosions.

**Aim:** To utilize optical coherence tomography of the anterior segment of the eye for the diagnosis and assessment of corneal wound healing processes.

## MATERIALS AND METHODS

This research was conducted between 2021 and 2023. It involved the examination of 46 patients with non-penetrating corneal injuries who were observed at the clinics of Bogomolets National Medical University. A control group consisting

of 15 healthy patients was also included. The research was carried out in compliance with ethical principles in accordance with the World Medical Association Declaration of Helsinki (2000), the basic principles of «Ethical Principles for Conducting Human Research» as defined by ICH GCP (1996), and Directive 86/609/EEC (1986). The study also adhered to the regulations of the Ministry of Health of Ukraine, including Orders No. 690 of September 23, 2009, No. 944 of December 14, 2009, No. 616 of August 3, 2012, as well as those approved by the Commission for Bioethical Expertise and Ethics in Scientific Research of Bogomolets National Medical University under Protocol No. 138 dated November 10, 2020. Informed consent was obtained from each patient for their participation in the study.

Data collection included demographic information of the patients, their occupations, the mechanism and duration of the trauma, the presence of recurrences, and the timing of seeking medical assistance. All patients underwent assessments of visual acuity, biomicroscopy, and evaluation of the conjunctiva and corneal status, as well as a fluorescein test. Biomicroscopic examination was used to assess the condition of the conjunctiva and cornea, as well as to localize the epithelial defect in corneal wound healing.

Using AS-OCT, we observed the corneal thickness and the size of the epithelial defect both before and after treatment. Corneal images were obtained using spectral-domain OCT with a wavelength of 830 nm and a scanning speed of 130,000 A-scans per second, providing an axial resolution of 5  $\mu$ m. It is important to note that during the examination, the area of injury was matched biomicroscopically before and after treatment, and images were captured in the same plane while maintaining the research protocol.

## RESULTS AND DISCUSSION

The study included 28 males (60.9%) and 18 females (39.1%), with ages ranging from 22 to 65 years (mean age  $41.5 \pm 2.4$ ). The average duration of symptoms before patients sought medical attention was  $2.2 \pm 1.2$  days. In terms of the type of trauma, non-occupational trauma was more com-

mon, occurring in 26 cases (56.5%), while occupational trauma accounted for 20 cases (43.5%). Among patients with occupational trauma, 50% did not use protective eyewear during work. The control group consisted of 15 healthy individuals with an average age of  $32.5 \pm 2.4$ .

The clinical characteristics of the patients, including visual acuity, localization of the injury, and corneal thickness, are presented in Table 1.

Table 1

Clinical characteristics of patients with corneal injuries

Localization of the injuries	The number of patients	Visual acuity in case of injury	Visual acuity after epithelium	Corneal thickness before treatment	Corneal thickness after treatment
Central	20	$0,38 \pm 0,03$	$0,82 \pm 0,02$	$488 \pm 131 \mu\text{m}$	$529 \pm 144 \mu\text{m}$
Paracentral	26	$0,67 \pm 0,06$	$0,94 \pm 0,04$	$513 \pm 125 \mu\text{m}$	$545 \pm 137 \mu\text{m}$

AS-OCT was performed for all patients on the day of their initial visit and after treatment.

Image of the cornea in the control group is presented in Fig. 1 and corresponds to a normal cornea. In the image, distinct layers are clearly distinguishable, including the tear film, epithelium, basement membrane, Bowman's layer, stroma, and Descemet's-endothelial complex. The corneal epithelium is represented by a weakly reflective layer, above which we observe a hyper-reflective layer corresponding to the tear film. Between the epithelium and the stroma, a highly reflective line is visualized, morphologically corresponding to the basement membrane, while a hypo-reflective line corresponds to Bowman's layer. The results indicate that the basement membrane appears as a hyper-reflective line, which aligns with its histological struc-

ture since it consists of various types of collagens (collagen types IV and VII) [7,8].

Identification of the basement membrane line serves as an important diagnostic criterion since its involvement in the pathological process affects the outcome of corneal trauma [9]. The next layer of the cornea is the stroma, which has a homogeneous and uniform structure across its entire plane, thanks to the content and arrangement of type 1 collagen. The Descemet's-endothelial complex corresponds to a hyper-reflective line located just below the stroma. Comparing the histological structure of the cornea with the obtained OCT images of the cornea allows for an accurate diagnosis of the depth of corneal damage, which subse-

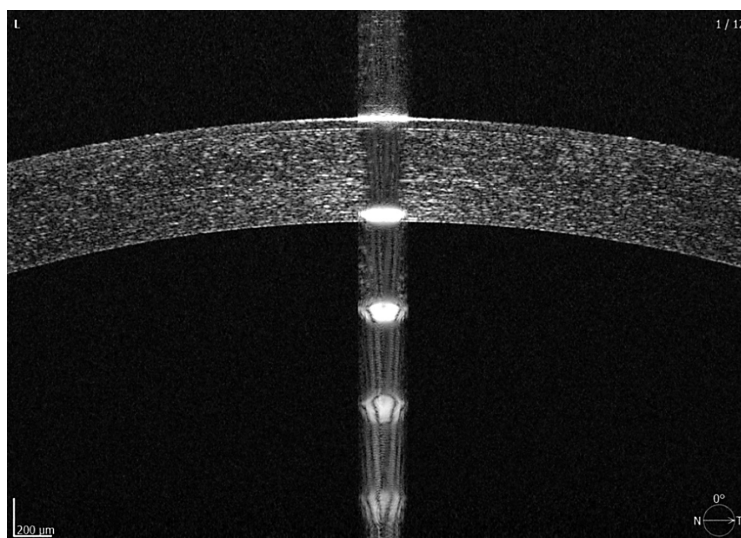
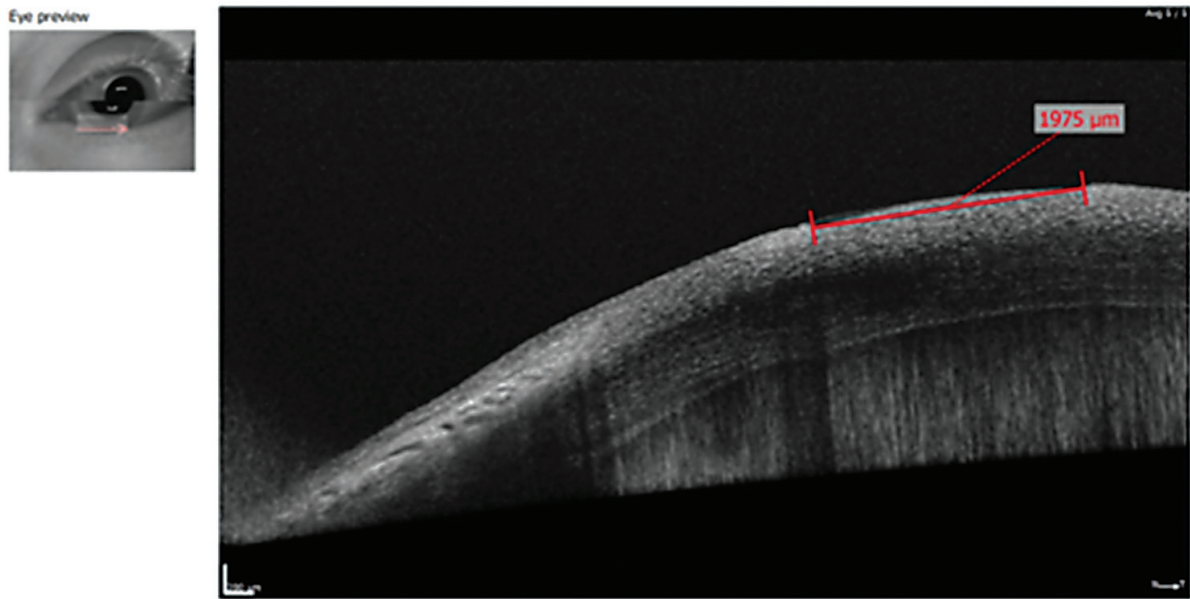


Fig. 1. Anterior segment optical coherence tomography (OCT) image depicting a healthy cornea



**Fig. 2.** AS-OCT image of traumatic corneal erosion, clinical case №3. A 30-year-old female patient sustained an injury from a tree branch impact. Upon examination, her visual acuity was 0.2 uncorrected. In the OCT image:

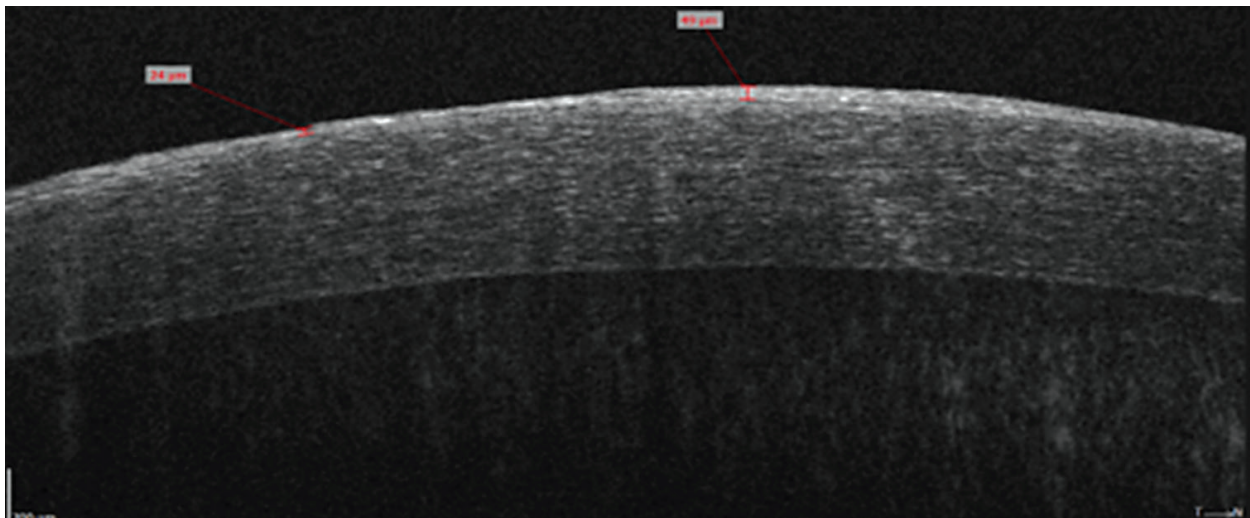
- 1) There is an epithelial layer defect.
- 2) The surface of the anterior stroma appears heterogeneous and mixed.
- 3) The reflectivity of the underlying stroma is hypo-reflective and disorganized

quently influences the treatment method and the consequences of the trauma [8,10].

During OCT examination of traumatic corneal erosion, in most cases, the following features were visualized: an irregularly shaped epithelial defect with uneven borders, an irregular mixed anterior surface of the stroma, heterogeneous reflectivity of the stroma, and corneal thinning. After treatment, the results corresponded to corneal re-epitheliali-

zation: thick and intact epithelium, hyper-reflective stroma, and a demarcation line confirming the wound healing process. After treatment, the corneal thickness was restored to  $(529 \pm 144 \mu\text{m})$ , which corresponds to the thickness of a healthy cornea.

Using OCT, traumatic corneal erosions with damage to the basal membrane (Fig. 3) were detected, which later clinically resulted in erosion



**Fig. 3.** AS-OCT of traumatic corneal erosion, clinical case 13. A 32-year-old patient, while working with metal, suffered an injury from a foreign metal body. Upon examination, visual acuity was 0.6 without correction. On OCT : 1) multiple irregularly shaped epithelial disruptions, 2) uneven basal membrane, with some areas thickened and others thinned, 3) heterogeneity in the reflective properties of the stroma

recurrence (one month after the initial visit). OCT in this case revealed multiple irregular epithelial disruptions and the absence of a uniform basal membrane line.

AS-OCT provides high-resolution, in vivo cross-sectional images of the cornea and anterior chamber of the eye, corresponding to the histological structure of the corneal tissue. It allows for the assessment of morphological and structural changes in various layers of the cornea in cases of trauma, inflammatory processes, and dystrophic changes, as well as after ophthalmic surgeries [9, 10, 11].

The use of OCT in traumatic corneal injuries is an important additional instrumental method of examination. With AS-OCT, we can assess the epithelialization of corneal layers, the depth and area of damage, and the involvement of the basal membrane in the pathological process, especially in cases of prolonged healing. In situations where the epithelium and basal membrane are restored, transparency and optical properties of the cornea are preserved [12]. On the other hand, prolonged inflammation and the inability to restore the basal membrane initiate corneal fibrosis, leading to a disruption of its optical properties. With OCT, we can observe the morphological structure of the cornea and the wound healing process, which allows us to predict the consequences of trauma.

## CONCLUSION

OCT is an informative additional diagnostic method for corneal injuries that allows for the evaluation of corneal morphology, including the status of the basal membrane, corneal thickness, and epithelialization. Based on these results, we can predict the course of corneal trauma and its possible consequences, enabling us to adjust treatment to prevent fibrosis development and minimize the consequences of the injury.

**Conflict of Interest.** All authors have no real or potential conflicts of interest (financial, personal, professional, or other interests) that could influence the subject or material described and discussed in this manuscript.

The study involved human participants. This research was approved by the local bioethics committee. Informed consent forms were obtained from all patients who participated in the study. The study was conducted in accordance with the Helsinki Declaration.

## REFERENCES

1. Barrientez B, Nicholas SE, Whelchel A, Sharif R, Hjortdal J, Karamichos D. Corneal injury: Clinical and molecular aspects. *Exp Eye Res.* 2019;186:107709. DOI: 10.1016/j.exer.2019.107709
2. Heath Jeffery RC, Dobes J, Chen FK. Eye injuries: Understanding ocular trauma. *Aust J Gen Pract.* 2022;51(7): 476-482. DOI: 10.31128/AJGP-03-21-5921
3. Park J, Yang SC, Choi HY. Epidemiology and Clinical Patterns of Ocular Trauma at a Level 1 Trauma Center in Korea. *J Korean Med Sci.* 2021;36(1):e5. DOI: 10.3346/jkms.2021.36.e5
4. Wilson SE. Corneal wound healing. *Exp Eye Res.* 2020;197:108089. DOI: 10.1016/j.exer.2020.108089
5. Dang DH, Riaz KM, Karamichos D. Treatment of Non-Infectious Corneal Injury: Review of Diagnostic Agents, Therapeutic Medications, and Future Targets. *Drugs.* 2022;82(2):145-167. DOI: 10.1007/s40265-021-01660-5
6. Ang M, Baskaran M, Werkmeister RM, Chua J, Schmidl D, Aranha Dos Santos V, Garhöfer G, Mehta JS, Schmetterer L. Anterior segment optical coherence tomography. *Prog Retin Eye Res.*, 2018;66:132-156. DOI: 10.1016/j.preteyeres.2018.04.002
7. Venkateswaran N, Galor A, Wang J. Optical coherence tomography for ocular surface and corneal diseases: a review. *Eye and Vis.* 2018;5:13. DOI:10.1186/s40662-018-0107-0
8. Pantaloni A, Pfister M, Aranha Dos Santos V, Sapeta S, Unterhuber A, Pircher N, Schmidinger G, Garhöfer G, Schmidl D, Schmetterer L, Werkmeister RM. Ultrahigh-resolution anterior segment optical coherence tomography for analysis of corneal microarchitecture during wound healing. *Acta Ophthalmol.* 2019;97(5):e761-e771. DOI: 10.1111/aos.14053
9. Bonnet C, Debillon L, Al-Hashimi S, Hoogewoud F, Monnet D, Bourges JL, Brézin A. Anterior segment optical coherence tomography imaging in peripheral ulcerative keratitis, a corneal structural description. *BMC Ophthalmol.* 2020;20(1):205. DOI: 10.1186/s12886-020-01466-1
10. Armarnik S, Mimouni M, Goldenberg D, Segev F, Meshi A, Segal O, Geffen N. Characterization of deeply embedded corneal foreign bodies with ante-

rior segment optical coherence tomography. Graefes Arch Clin Exp Ophthalmol. 2019;257(6):1247-1252. DOI: 10.1007/s00417-019-04309-y

11. Simon SM, Fung Rosalind MK, Stewart, Sandeep K. Dhallu, Dawn A. Sim, Pearse A. Keane, Mark R. Wilkins, Stephen J. Tuft. Anterior Segment Optical Coherence Tomographic Angiography Assessment of Acute Chemical Injury. American Journal of Ophthalmology, 2019;205, 165-174. DOI 10.1016/j.ajo.2019.04.021
12. Fung SSM, Stewart RMK, Dhallu SK, Sim DA, Keane PA, Wilkins MR, Tuft SJ. Anterior Segment Optical Coherence Tomographic Angiography Assessment

of Acute Chemical Injury. Am J Ophthalmol. 2019;205:165-174. DOI: 10.1016/j.ajo.2019.04.021.

## ДОСВІД ЗАСТОСУВАННЯ ОПТИКО-КОГЕРЕНТНОЇ ТОМОГРАФІЇ ПРИ ТРАВМАТИЧНИХ ПОШКОДЖЕННЯ РОГІВКИ

*Гавриляк І. В., Жабоедов Д. Г., Гребень Н. К.*

*Національний медичний університет імені О.О. Богомольця, Київ, Україна*

*irengavriliak19@gmail.com*

**Актуальність.** Травма ока є однією з найпоширеніших причин монокулярного порушення зору та сліпоти в усьому світі. Сучасна класифікація поділяє травму ока на дві групи відкрита (проникаюча) і закрита (непроникаюча) трама ока. На діагностичному етапі важливим є ретельне обстеження і встановлення відповідного діагнозу до існуючої класифікації, що впливає на подальшу тактику ведення пацієнта та результат лікування. Оптична когерентна томографія (ОКТ) дозволяє отримати зображення тканин ока в режимі реального часу з високою роздільною здатністю. У нашому дослідженні відображено досвід використання оптичної когерентної томографії при травматичних пошкодженнях рогівки як додаткового методу оцінки глибини та площі пошкодження, моніторингу епітелізації ерозій рогівки.

**Ціль:** Застосування оптико-когерентної томографії переднього відрізка ока в діагностиці та оцінці епітелізації ран рогівки.

**Матеріали та методи.** Обстежено 46 пацієнтів з непроникаючими травмами рогівки, які спостерігалися на базі клінік НМУ імені О.О. Богомольця. Контрольну групу склали 15 здорових пацієнтів. Збір даних включав демографічні дані пацієнта, професію, механізм і тривалість травми, наявність рецидивів, період звернення за медичною допомогою. Всім пацієнтам проведено визначення гостроти зору, біомікроскопію, оцінку стану кон'юнктиви та рогівки, флюоресцеїновий тест. За допомогою ОКТ переднього відрізка спостерігали за товщиною рогівки та розміром дефекту епітелію до і після лікування.

**Результати.** При проведенні оптико-когерентної томографії при травматичній ерозії рогівки в більшості випадків візуалізувався дефект епітелію неправильної форми з нерівномірними краями, неправильна змішана передня поверхня строми, неоднорідна відбивна здатність строми і стоншення рогівки. Після лікування були отримані результати відповідно до епітелізації рогівки: товстий інтактний епітелій, гіперрефлексивна строма та демаркаційна лінія, що підтверджує процес загоєння рани. Після лікування товщина рогівки відновлювалася до  $(529 \pm 144 \text{ мкм})$ , що співставляється з товщиною здорової рогівки.

**Висновки.** ОКТ є інформативним додатковим методом діагностики травм рогівки, що дозволяє оцінити морфологічну структуру рогівки: стан базальної мембрани, товщину рогівки та її епітелізацію. Завдяки даним результатам ми можемо прогнозувати перебіг травми рогівки та можливі її наслідки, корегувати лікування з для запобігання розвитку фіброзу та мінімізування наслідків травми.

**Ключові слова:** травма ока, ерозія рогівки, оптико-когерентна томографія, епітелізація рогівки.